

# Management of Vaginal Atrophy with Intravaginal Light-Emitting Diodes (LEDs)

<sup>1</sup> Pablo Naranjo García, <sup>2</sup>Jorge Alberto Elias, <sup>3</sup>Jorge Gaviria Parada, <sup>4</sup>Daniel Zarza Lucíañez, \*Hernan  
Pinto

<sup>1</sup> Elite Laser Clinic. Madrid, Spain

<sup>2</sup>Gynesthetic Health and Aesthetic Center. Buenos Aires, Argentina

<sup>3</sup>Photomedicine Institute. Teknon Medical Center. Barcelona, Spain

<sup>4</sup>Laser Department. Vithas Nisa Pardo de Aravaca Hospital. Madrid

\*i2e3 Biomedical Research Institute. Barcelona, Spain

\*Corresponding author: Hernan Raul Pinto

\*Email: [esanchez@i2e3.com](mailto:esanchez@i2e3.com)

## **Abstract**

*Dryness is one the symptoms associated with vaginal atrophy, a condition related to low levels of estrogen, which affects up to 57% of postmenopausal women. The study aimed to evaluate novel intravaginal light-emitting diodes for vaginal tissue regeneration and treatment of symptoms associated with vaginal atrophy, as well as the reliability of this procedure for medical centers that do not have the treatment options to treat their patients with intravaginal CO2 or Er:YAG fractional lasers, or for home device treatments. The study included women with vaginal dryness treated with intravaginal light-emitting diodes device to stimulate vaginal tissue regeneration, for six weeks, with two sessions per week and follow-up for a month. Variables assessed: Distance urethra-vagina, tissue thickness, vascularization, Female Sexual Function Index, the Most Bothersome Symptom (MBS) and Vaginal Health Index. Thirty women were included (mean age 46.0±10.6 years). One month after last LED session, differences from baseline were statistically significant in Vaginal Health Index scale (p=0.0025), Female Sexual Function Index (questions of lubrication and pain (p<0.001)), distance urethra-vagina (P = 0.0289) and*

*vascularization ( $P = 0.0159$ ). Intravaginal light-emitting diodes appear to be a feasible, safe and effective procedure that induces a significant improvement of vaginal atrophy symptoms.*

### **Keywords**

*Genitourinary syndrome of menopause; vaginal atrophy; vaginal regeneration; low-power light therapy; light-emitting diodes phototherapy*

## **I. Introduction**

The introduction of new medical devices, offers the possibility to improve treatments, obtaining better results and offering greater satisfaction to patients. This would be the case of intravaginal light-emitting diodes (LEDs) devices adapted to the vaginal atrophy treatment.

Vaginal Atrophy (VA) is a common condition that is particularly prevalent during menopause that affects approximately 15% of premenopausal women and up to 57% of postmenopausal women. One of the most frequent symptoms is vaginal dryness, which can affect the quality of life of patients and their sexual relationships [1]. Other symptoms are burning, irritation, lack of lubrication, discomfort or pain, and dysuria. Symptomatology of VA may vary from bothersome to debilitating symptoms, thus it makes treatment essential. Choice of therapy will depend on the severity of symptoms, the effectiveness, and safety of therapy, taking into account patient's preference.

Some studies have reported the use of LED phototherapy for the rejuvenation of chronological and photodamaged skin,[2] and reducing pain, including postoperative pain, postoperative edema and inflammation [3].We

carried out a study for the VA treatment with a group that received an intravaginal LED session after the laser procedure, to diminish the laser side effects, and another group with laser alone; immediately after treatment, differences in edema and inflammation were statistically significant when both groups were compared [4].

This study aimed to evaluate the effect of intravaginal LEDs devices with different wavelengths for VA management. The hypothesis was that this treatment could be a safe and reliable option for those medical centers that do not have the possibility to treat their patients with intravaginal CO<sub>2</sub> or Er:YAG fractional lasers or for home device treatments.

## II. Material and Methods

This was a prospective, multi-center and single arm study that was conducted at Elite Laser Clinic (Madrid, Spain), Gynesthetic Health and Aesthetic Center (Buenos Aires, Argentina), Photomedicine Institute at Teknon Medical Center (Barcelona, Spain), and Laser Department at Vithas Nisa Pardo de Aravaca Hospital (Madrid, Spain). Study participants included women (n=30) with symptoms of dryness related to VA, with or without menopause, able to understand the study related information and agreed to participate in the study. Key exclusion criteria included previous hormonal or other treatments for VA. During six weeks, all patients underwent a total of twelve sessions with novel intravaginal LEDs, two sessions per week.

The study was conducted in accordance with the principles set forth in the current revised version of the Declaration of Helsinki, with the Good Clinical Practice (GCP) and in compliance with all applicable laws and regulatory requirements relevant to the use of devices in Spain and Argentina. Individual subject records were maintained in the investigator's Sources Documents. The CRF did not include any personal data.

### *Study protocol*

Consecutive patients were invited to participate in the study. After agreeing and once the need for treatment was confirmed, patients underwent twelve sessions with the Intravaginal LEDs model Floreo® (Qlarité SAS, Paris, France), two sessions per week, for total six weeks of treatment. (Figure 1)

### *Treatment procedures*

Intravaginal Floreo® LEDs protocol: 3 min with blue LED (415 nm), 3 min with red LED (660 nm) and 3 min with infrared LED (850 nm).

### *Data assessments*

Variables analyzed: age, maternity (births, abortions, maximum fetal weight), body mass index (BMI), vaginal tissue vascularization, symptoms (dyspareunia dryness and stinging), vaginal tissue characteristics (pH and humidity), score of pain, score of lubrication, vaginal epithelium wall thickness: epithelium distance at AA (point located 3 cm proximal to external urethral meatus on anterior vaginal wall, corresponds to urethrovesical crease), epithelium distance at AP (point located in the midline of the posterior vaginal wall 3cm proximal to the hymen) and distance between urethra to vagina.

Symptoms were assessed with the most bothersome symptom (MBS) tissue characteristics with the Vaginal Health Index Scale (VHIS), the score of pain and lubrication with the Female Sexual Function Index (FSFI), a brief of 19-item self-report measure of female sexual function that provides scores on six domains of sexual function as well as a total score. The thickness and tissue vascularization were assessed with a Mindray echography model M5 with two Probes. The Linear Probe 10-12MHz was used for the front of the vagina-urethra and the other distances were measured with a Convex Probe 3.5-5 MHz. The tissue vascularization evaluation was carried out with a Power Doppler duplex.

### Study procedures

**Basal assessments:** Before treatment the variables evaluated were MBS, VHIS, FSFI, a transvaginal echography to measure the distance from urethra to vagina, and the thickness AA and AP, and intravaginal Power Doppler to evaluate the tissue vascularization. **Post treatment (immediately after the last treatment):** all patients underwent a transvaginal echography to evaluate the tissue thickness AA and AP, and a Power Doppler to

assess the tissue neovascularization. One month post twelve LEDs sessions: the investigators carried out the same basal tests. Adverse events were assessed at all visits. Statistical analysis included appropriate measures for statistical significance (Student's paired two-sample t test) using the standard cutoff for significance of  $P < 0.05$  via Microsoft Excel.

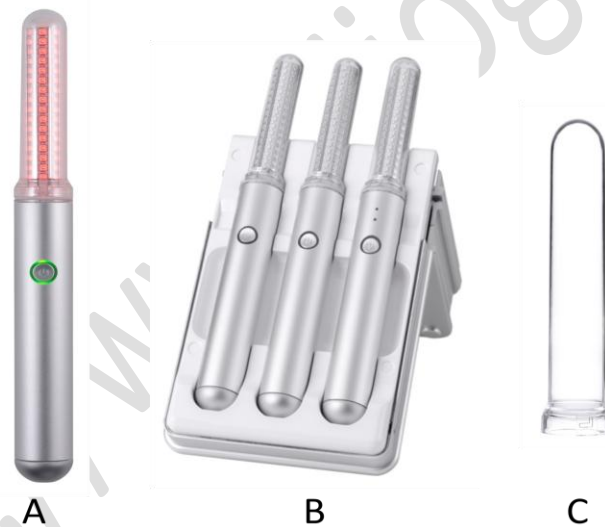

Figure 1: Floreo® LED device (Qlarité SAS. Paris, France) A: Floreo® red LED device. B: Floreo® LEDs platform with 3 devices: blue, red and infrared. C: Floreo® LED protector.

### III. RESULTS

The study included 30 women with mean results of age  $46.0 \pm 10.6$  years. All patients were treated with twelve sessions of Intravaginal Floreo® LEDs. Patients were assessed at baseline and one month after treatment (12 LEDs sessions).

#### *Qualitative of VHIS assessments*

At baseline, the Vaginal Health Index Scale (VHIS) in the study population had a mean value of  $18.00 \pm 3.54$  (range 11-23). One month after treatment; the mean value was  $21.43 \pm 2.87$  (range 15-25). Improvement was statistically significant ( $P = 0.0001$ ).

#### Anatomical measures

Baseline assessments: Mean value of distance urethra-vagina was  $49.10 \pm 10.10$ mm, vascularization  $3.10 \pm 0.92$ microvessels per  $\text{mm}^2$ , thickness AA  $27.17 \pm 13.73$ mm and thickness AP  $27.17 \pm 12.82$ mm.

#### *a) Post treatment assessments*

Distance urethra to vagina: Immediately after treatment, mean value of distance urethra-vagina was  $57.53 \pm 10.45$ mm and the differences with basal mean value were statistically significant ( $P = 0.0024$ ).

Vascularization: Mean value was  $3.33 \pm 0.92$ microvessels per  $\text{mm}^2$ , and the differences with basal mean value were not statistically significant ( $P = 0.3369$ ).

Thickness AA: Mean value of tissue thickness AA was  $29.47 \pm 13.97$ mm, and the differences with basal mean value were not statistically significant ( $P = 0.5227$ ).

Thickness AP: Mean value of tissue thickness AP was  $29.30 \pm 12.95$ mm, and the differences

with basal mean value was not statistically significant ( $P = 0.5245$ ).

#### *b) At one month post treatment*

Distance urethra to vagina: At one month after 12 LED sessions, mean value of distance urethra-vagina was  $54.93 \pm 10.05$ mm and the differences with basal mean value were statistically significant ( $P = 0.0289$ ).

Vascularization: Mean value was  $3.70 \pm 0.95$ microvessels per  $\text{mm}^2$ , and the differences with basal mean value were statistically significant ( $P = 0.0159$ ).

Thickness AA: Mean value of tissue thickness AA was  $32.20 \pm 13.25$ mm, and the differences with basal mean value was not statistically significant ( $P = 0.1542$ ).

Thickness AP: Mean value of tissue thickness AP was  $32.83 \pm 12.71$ mm, and the differences with basal mean value was not statistically significant ( $P = 0.0913$ ).

#### Subjective assessments

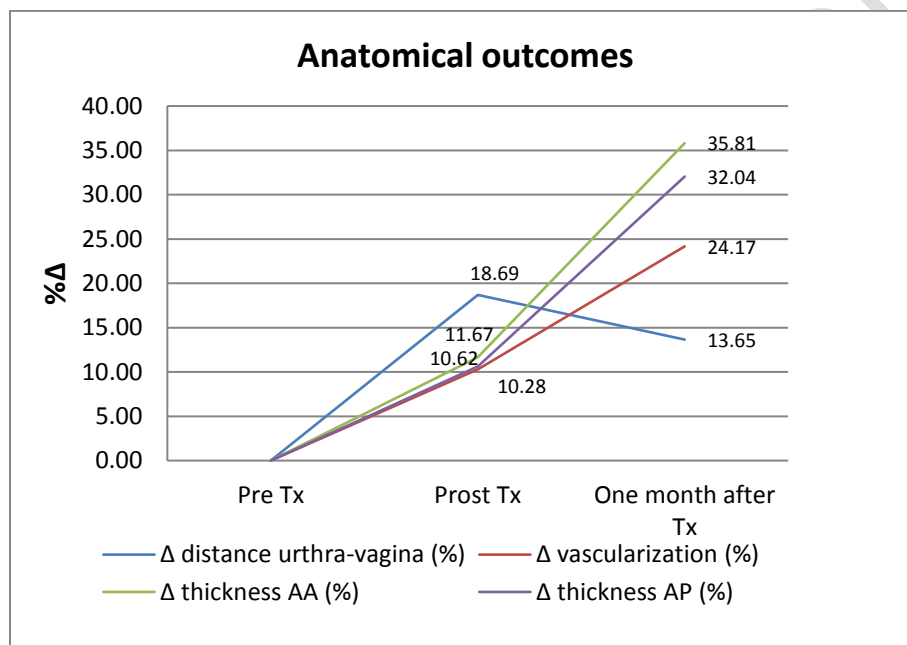
At baseline, the Female Sexual Function Index (FSFI) mean value was  $52.10 \pm 21.99$  (range 20-89) and at one month post-treatment  $57.57 \pm 24.59$  (range 2-95), differences were not significant ( $p = 0.3675$ ). Analyzing the differences by type of question, we found that the patients improved their vaginal and sexual symptoms, answers related to lubrication (questions 7 to 10) and pain (questions 17-19), the improvement remained statistically significant ( $p < 0.001$ ).

At baseline, the most bothersome symptoms reported by patients at moderate level were: Dryness 33%, stinging 53%, pain 17%, dyspareunia 27%; dysuria and postcoital bleeding were 0%. Severe symptoms: Stinging 10%, pain 53%, dysuria 13%, dyspareunia

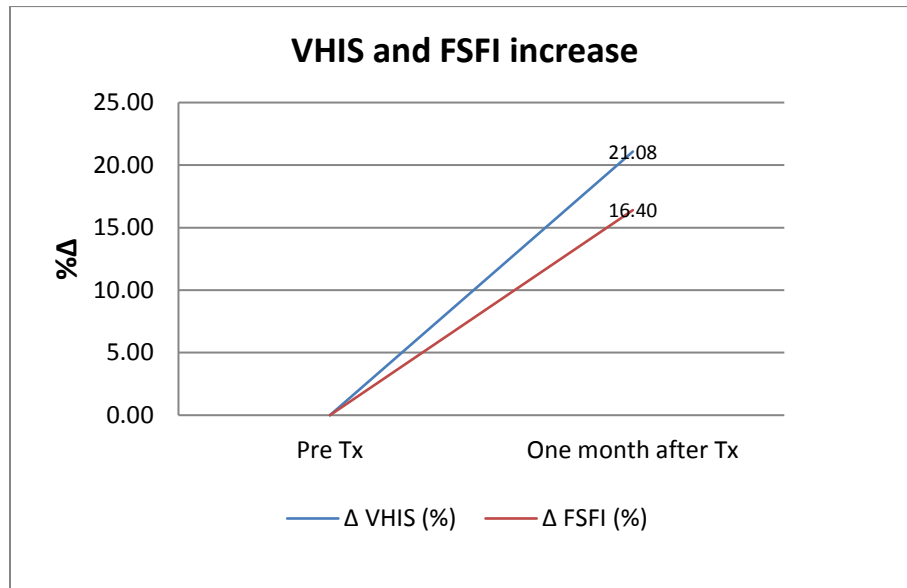
20%; dryness and post coital bleeding were 0%. At one month after treatment, the MBS reported at moderate level were: Dyspareunia 10% and other symptoms were 0%. Severe symptoms: Dyspareunia 3% and other symptoms were of 0%.

The average of the improvement reported by patients was  $6.47 \pm 2.16$ .

The percentages of increase of all anatomical measures, (Figure 2) and FSFI and VHIS,(Figure 3) were calculated, immediately after LED session and one month post treatment.



**Figure 2:** Percentage of increase ( $\% \Delta$ ) of the anatomical measures after one month of treatment. Tx: treatment.



**Figure 3:** Percentage of increase ( $\% \Delta$ ) of VHIS and FSFI results after one month of treatment. VHIS: Vaginal Health Index Scale; FSFI: Female Sexual Function Index; Tx: treatment.

### *Safety findings*

The treatments did not require analgesia/ anesthesia. There were no treatment complications and adverse effects. Patients did not refer pain with LED treatment.



#### IV. DISCUSSION

In this study LEDs treatment was associated with the improvement of vaginal health and amelioration of symptoms of VA, resulting in an improvement of vaginal epithelium thickness and vaginal tissue vascularization. Patients improved their vaginal and sexual symptoms, reporting a decrease in the severity of symptoms. Improvement was maintained at the 4-week follow-up.

Immediately after treatment, the anatomical assessments did not show signs of edema or inflammation, and at one month after last LEDs session, all patients had an improvement of their symptoms and the quality of vaginal tissue. Vaginal Health Index scale improved, and the differences with the baseline were statistically significant ( $p=0.0001$ ), as well as the questions of the Female Sexual Function Index related to lubrication and pain ( $p<0.001$  both). The anatomical assessments showed an increase statistically significant of the distance urethra-vagina and vascularization ( $P=0.0289$  and  $P=0.0159$  respectively) and no statistically significant of tissue thickness AA and AP ( $P=0.1542$  and  $P=0.0913$  respectively), but the tissue had an increase of thickness from baseline of 35.81% and 32.04% respectively.

In this study, we also include several validated scores such as the scale for the assessment of the most bothersome symptom (MBS), the Vaginal Health Index Scale (VHIS) and the Female Sexual Function Index. The MBS was included in the study, because it is useful to know what women perceive the symptoms of

of their vaginal atrophy condition. The identification of the MBS may help in simplifying, individualizing the decision to treat, and thus improving the management of VA [5]. FSFI scores may provide greater ability to assess treatment specificity; one potential weakness is that FSFI is appropriately used only for subjects who have had some level of sexual activity during the measurement period [6].

Taking into account that this procedure do not create ablation, edema or inflammation, compared with intravaginal CO<sub>2</sub> or Er:YAG fractional lasers, our results support the rationale behind LEDs, based on by its reported efficacy at a cellular and subcellular level, particularly for the 660 nm and 850nm wavelengths. As some studies on skin rejuvenation have reported that LED phototherapy may improve blood flow, neovascularization, promote collagenesis, and reduce pain, as well as inflammation,[7]our study showed the same benefits for VA management.

Echography and Power Doppler were used to assess the thickness of the epithelium and to evaluate the change of vascularization after the procedure on the treated structures; only the resonance is better that the ultrasound as a diagnostic test, but we decided not to use it in this study as this is a procedure not free of risks of ionizing radiation.

We have not found published studies using LEDs for vaginal atrophy that may be used to compare our results; thus would be needed more research in this line. In the literature there are some studies that have been conducted with LED devices for skin



rejuvenation. Weiss et al., conducted a one study using a 590-nm LED array, patients improved facial texture and results were confirmed by digital microscopy [8]. Goldberg et al., using red and infrared wavelengths, showed that these LEDs may be effective for improvement in skin texture.[2] Other studies have included the use of LED combined with laser procedure for the treatment of vaginal atrophy, for reducing the laser side effects such as pain and edema, with statistically significant differences when compared with laser results [4]. De la Torre et al., used the LED alone in a study for women with stress urinary incontinence (SUI) and their results confirmed a treatment success of 84% [9]. Limitations of this study include the relatively small number of participants enrolled, lack of a control arm, the short follow-up and the lack of similar studies to compare. Nevertheless, findings of improvement of VA symptoms were highly significant.

## V. CONCLUSION

This protocol appears to be safe and effective for VA treatment. The use of LEDs could be a reliable option for medical centers that do not have the treatment options for their patients with intravaginal CO<sub>2</sub> or Er:YAG fractional lasers or other energy based devices and also it is an application with technology for home use. However, further studies with more samples, longer follow-up period, control arm and LEDs treatment alone, should be carried out.

## AUTHOR DISCLOSURE STATEMENT

The authors declare that there is no conflict of interests regarding the publication of this paper.

## ACKNOWLEDGMENTS

The authors want to thank all their collaborators and specially the i2e3 Biomedical Research Institute medical writer team.

## VI. References

- [1].Edwards D, Panay N. Treating vulvovaginal atrophy/genitourinary syndrome of menopause: how important is vaginal lubricant and moisturizer composition? *Climacteric*. 2016 Apr;19(2):151–61.
- [2].Goldberg DJ, Amin S, Russell BA, Phelps R, Kellett N, Reilly LA. Combined 633-nm and 830-nm led treatment of photoaging skin. *J Drugs Dermatol*. 2006 Sep;5(8):748–53.
- [3].Kim W-S, Calderhead RG. Is light-emitting diode phototherapy (LED-LLLT) really effective? *Laser Ther*. 2011;20(3):205–15.
- [4].Naranjo P, Elias JA, Gaviria-Parada J, Zarza-Lucianez D, Pinto HR. Anatomical outcomes of therapy with LEDs in combination with intravaginal CO<sub>2</sub> vs Er\_YAG fractional lasers to treat vaginal atrophy. *Int J Surg Sci*. 2018;2(1):05–9.

- [5].Palma F, Xholli A, Cagnacci A. The most bothersome symptom of vaginal atrophy: Evidence from the observational AGATA study. *Maturitas*. 2018 Feb;108:18–23.
- [6].R. Rosen et al. The Female Sexual Function Index (FSFI): A Multidimensional Self-Report Instrument for the Assessment of Female Sexual Function. *J Sex Marital Ther*. 2000 Apr;26(2):191–208.
- [7].Whelan HT, Buchmann E V., Dhokalia A, Kane MP, Whelan NT, Wong-Riley MTT, et al. Effect of NASA Light-Emitting Diode Irradiation on Molecular Changes for Wound Healing in Diabetic Mice. *J Clin Laser Med Surg*. 2003;21(2):67–74.
- [8].Weiss RA, Weiss MA, Geronemus RG, McDaniel DH. A novel non-thermal non-ablative full panel LED photomodulation device for reversal of photoaging: digital microscopic and clinical results in various skin types. *J Drugs Dermatol*. 2004;3(6):605–10.
- [9].de la Torre S, Miller LE. Multimodal vaginal toning for bladder symptoms and quality of life in stress urinary incontinence. *Int Urogynecol J*. 2017 Aug 29;28(8):1201–7.